

Original

Orthopaedic involvement in viper bite in children in Greece. Report of four cases

Vasiliki Chatziravdeli^{1*}, Dimitrios Arapoglou², Christos Gekas², Vasileios Kalaitzis², Panagiotis Dionellis²

¹*Sports Injuries Unit, KAT Attica General Hospital, Athens, Greece*

²*Orthopaedic Department, Ippokratio General Hospital of Thessaloniki, Thessaloniki, Greece*

Abstract

Background: Venomous snake bites can cause symptoms like pain, swelling, and potential systemic and limb-threatening complications such as compartment syndrome. The paper discusses the role of orthopedic surgeons in managing severe cases where patients develop compartment syndrome.

Case Presentation: Four children aged 10 months to 11 years were treated for venomous snake bites at a public hospital. All bites were on their upper limbs, with the children bitten in various home environments. Symptoms included pain, swelling, ecchymosis, and drowsiness without hemodynamic instability. Antivenom was administered, and two children required emergency fasciotomies due to developing compartment syndrome.

Fasciotomies were performed on two patients, involving multiple incisions to release pressure in the hand and forearm compartments. In one patient, the incision extended to the humerus due to swelling.

The two children who underwent fasciotomy experienced immediate relief, with reduced pain, swelling, and paresthesia. One child developed hydrothorax, which was managed with a drain. For patients without compartment syndrome, neurovascular assessments showed improvement after antivenom treatment. The patients remained in the PICU for 2-7 days and, when stable, were transferred to the pediatric department. No major complications were noted except for the hydrothorax.

Conclusion: The diagnosis of snake envenomation is based on history, clinical symptoms, and laboratory tests. Treatment includes close monitoring and supportive care with antivenom serum administration. Compartment syndrome is a potential complication, and



Corresponding
author

Vasiliki Chatziravdeli
v.chatziravdeli@gmail.com

high vigilance is warranted. Early detection and management are crucial for successful recovery.

Viper bites in children require prompt and thorough management. The involvement of an orthopedic surgeon is key to preventing severe outcomes and preserving limb function.

Keywords

Viper bite; Greece; children; compartment syndrome; antivenom

Introduction

Eight venomous snake species can be found in Greece, and the most common of these species are members of the *Viperidae* family. *Vipera ammodytes* is considered the most dangerous because its venom is highly cytotoxic and neurotoxic, and can be found throughout the country. *Montivipera xanthina* (Ottoman viper) is the largest viper species found in the region and has highly toxic venom.^{1,2} Approximately 200 people are bitten every year, but only 6 people died from 2000-2014 (Hellenic Statistical Authority-ELSTAT data). The most common symptoms include two symmetrical bite marks, pain, local edema, ecchymosis, dizziness, nausea, vomiting, and regional lymph node enlargement.³ Complications include blister formation on the skin due to swelling and necrosis, compartment syndrome, respiratory distress, palpitations, and syncope.⁴ In this context, the role of the orthopedic surgeon consists of close assessment of the neurovascular status of the affected limb and prompt treatment via surgical fasciotomies in the event of compartment syndrome.

CASE 1

A 2-year-old child presented in the emergency department with a painful and swollen right hand. The parents reported hearing the child suddenly crying while playing in his room without any history of a fall or other trauma. While screening the room, they found a viper between the child's toys. During clinical examination, distinct fang marks were found in the child's right index finger (**Fig. 1a**). The patient was hemodynamically stable, with swelling, ecchymosis, and pain in his right

hand. He was started on intravenous (IV) fluids and antibiotics, and the arm was immobilized in a conventional splint with non-restricting bandaging. Tetanus prophylaxis was covered by his prior inoculation. He was moved to the pediatric intensive care unit (PICU), where he received antivenom serum. Respiratory, cardiovascular, and renal function were closely monitored, along with electrolyte balance and coagulation. The limb was slightly elevated, and hourly checks were performed regarding oedema progression, pain in passive stretching of the hand, paresthesia, tightness of the hand compartments, and perfusion. Two hours later, the child developed compartment syndrome of the right hand, with excess swelling, pain in passive movement, and extreme tension of the hand, and emergency fasciotomies were performed. Two dorsal hand incisions between the second and fourth metacarpal were made, and three volar incisions, one releasing the carpal tunnel, one over the thenar, and one over the hypothenar, and all hand compartments were released (**Fig. 1b**). The limb's neurovascular status improved over the following days, the swelling and tension subsided, and the incisions were sutured 3 days later, without signs of infection. Full recovery of hand function was noted without any residual deficit, and the child was discharged after 10 days.

CASE 2

An 11-year-old boy was transferred to our hospital from a summer camp because he was bitten by a venomous snake on the right hand while playing outdoors. On arrival, he was hemodynamical-

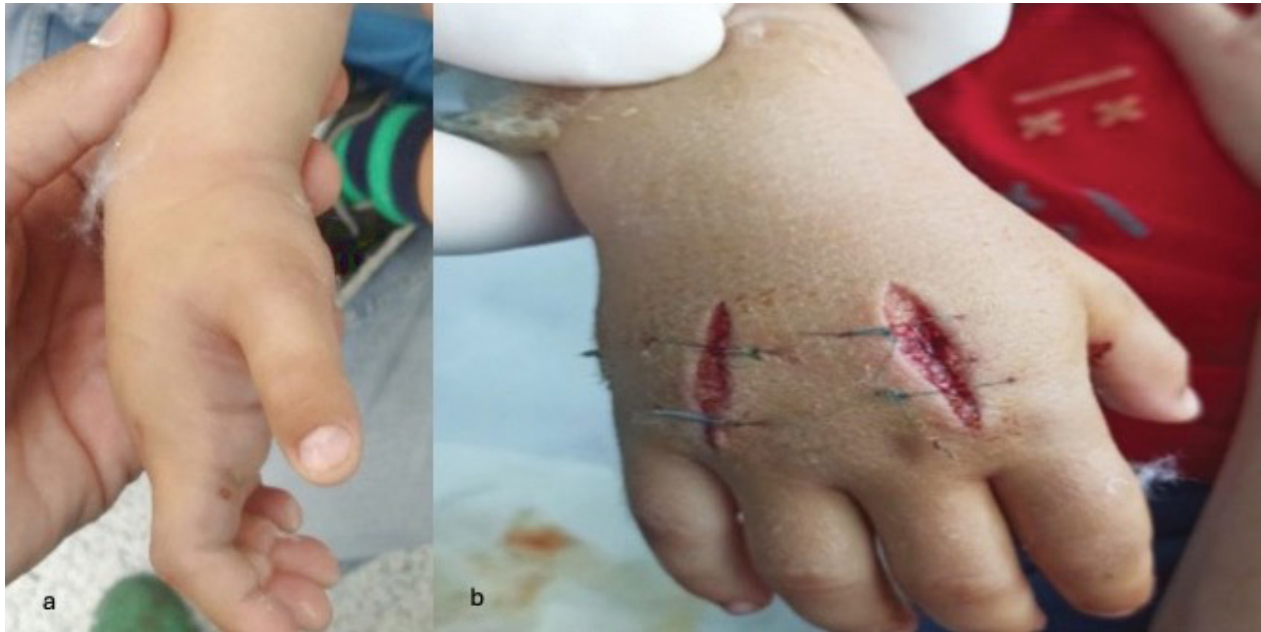

Figure 1: a. Distinctive bite marks in the right index and excess swelling of the hand before compartment release, b. Dorsal fasciotomies of the hand over the second and fourth metacarpals for the release of the interosseous hand compartments

ly stable, the affected arm was immobilized with a non-constricting splint, and there were distinctive bite marks on the dorsum of his hand. The hand was painful, bruised, and swollen. He was started on IV fluids and electrolytes, antibiotics, received tetanus prophylaxis, and was transferred to the PICU. There, he received antivenom serum under close monitoring without any adverse events. Serial clinical examinations demonstrated deterioration of the limb's neurovascular status, with increased swelling and ecchymosis of the right hand up to the forearm and humerus, and the patient developed paresthesia in the median nerve distribution. Emergency fasciotomies were performed 8 hours after presentation. The decision was based on clinical signs of paresthesia in the median nerve distribution, excess edema, extreme tension, and pain in passive muscle stretching.

Surgical release of the hand compartments included two dorsal incisions between the second and fourth metacarpals for the release of the interosseous compartments, one volar incision in the thenar area (thenar and adductor compartment), one in the hypothenar area (hypothenar compart-

ment), and one for carpal tunnel release. The four forearm compartments were released by one volar incision and one dorsal incision. The volar incision in the forearm was extended to the humerus, releasing the lacertus fibrosus and the humeral compartments due to expansion of the swelling to the humerus. Only the incision for carpal tunnel release was sutured during the index operation, and the rest were left open. Subcutaneous tissue and muscles were bruised (Fig. 2).

There was immediate relief from pain, and the edema subsided in three days. The skin incisions were sutured uneventfully after three days, with no signs of infection or muscle damage/necrosis. Cardiovascular and renal function was stable, without signs of rhabdomyolysis, but on the third day of his hospitalization, the patient developed hydrothorax, which was treated with a drain. He remained in the PICU for seven days for close monitoring and was later transferred to the pediatric department after removal of the thoracostomy drain until his discharge. Full limb recovery was observed, and the patient regained normal sensation and pain-free full range of motion of the

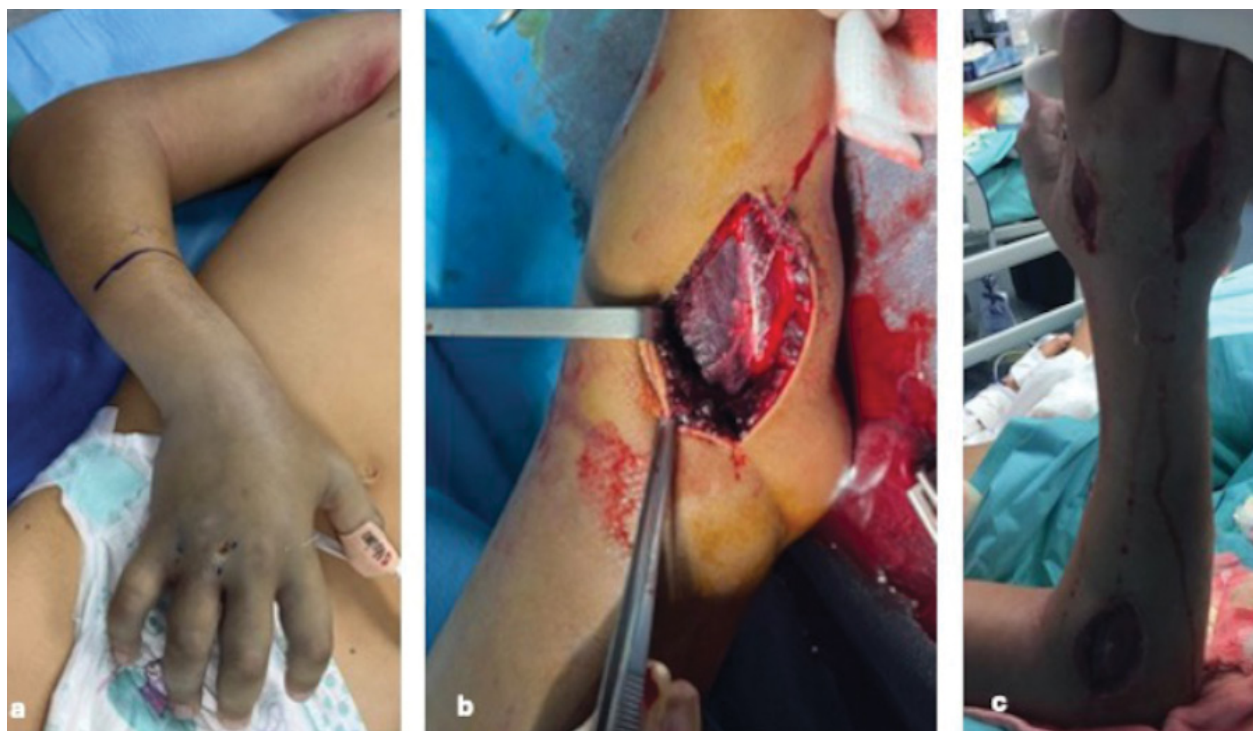


Figure 2: a. Bite marks in the dorsum of the hand, edema, ecchymosis, b. Intraoperative release of dorsal forearm compartments, with subcutaneous and muscle bruising, c. Dorsal skin incisions for hand and forearm fasciotomies

upper limb without any neurovascular deficit, a week after the fasciotomies.

CASE 3

A 10-month-old child presented in the emergency department after being bitten by a venomous snake on the wrist. The child was playing in an outdoor plastic swimming pool and was bitten on the wrist by a snake in the pool. On arrival, the infant had drowsiness, with diminished response to pain, and the right forearm was bruised and swollen (**Fig. 3**). His vital signs were normal, and supportive care was initiated, with IV fluids, electrolytes, antibiotics and tetanus prophylaxis. The arm was immobilized with a non-constricting splint, and the child was moved to the PICU. Two doses of antivenom serum were administered without any adverse events, along with analgesia (paracetamol) and slight limb elevation. Gradually, the child's response to stimuli improved, and the swelling was stable with improvement during serial examinations. Because of his young

age, the main clinical signs observed were lack of pain in passive muscle stretching, good capillary refill, and gradual improvement of local edema without excess tension of the hand and forearm. Paresthesia could not be assessed because of his young age. No surgical intervention was necessary. Three days later, he was hemodynamically stable, alert, with normal response, and with normal right arm function. He was moved to the pediatric clinic until final discharge.

CASE 4

A 4-year-old girl was transferred to our hospital for treatment and monitoring after being bitten in the hand by a snake while playing in her backyard. On arrival, she was fully alert (Glasgow Coma Scale 15/15), with normal vital signs, and her right forearm was immobilized in a splint. She had swelling and pain in her arm without paresthesia. She received supportive care, with IV fluid and electrolyte administration, along with antibiotics and tetanus prophylaxis. She remained in the

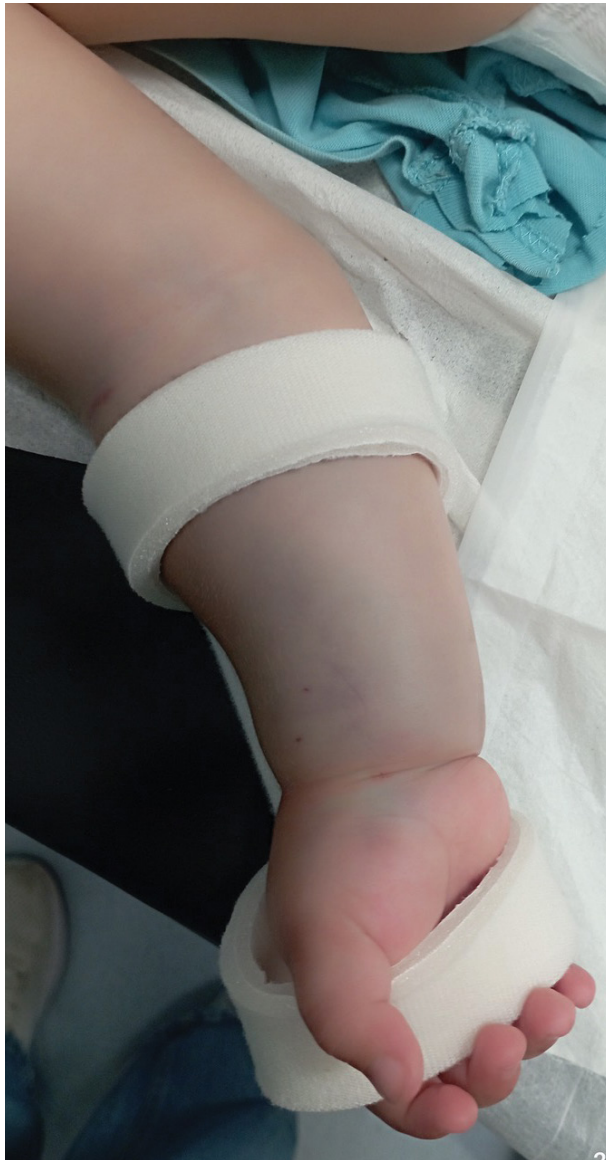

Figure 3: Bite marks on the volar part of the wrist and local edema and ecchymosis of the child who did not require fasciotomy

PICU for two days, where antivenom serum was given. Serial hourly neurovascular examinations demonstrated improvement of the limb's status, and no surgical intervention was necessary. After antivenom serum administration and slight limb elevation the swelling progression came to a halt and gradually subsided. She was discharged from the PICU two days later and stayed for monitoring in the pediatric clinic for five more days until final discharge. There were no systemic or local

complications, and full arm function was recovered.

Discussion

Viper bites in our region are not very uncommon. According to the 2014 ELSTAT, 48 patients were treated for snake envenomation. Even though approximately 200 people are bitten by vipers each year, there were only 6 deaths from 2000 – 2014. Snake venom is a complex mixture of proteins, polypeptides, and bioactive molecules with various toxicities and pathophysiological effects. Snakes from the *Viperidae* family mainly contain venom with hematotoxic and cytotoxic effects.⁵ No test is available to date to detect which patients will develop systemic envenomation, and diagnosis is based on history, clinical symptoms, and laboratory tests. Treatment is based on the combination of detailed history, clinical examination of the affected extremity, and close monitoring of cardiovascular, respiratory, and renal function. Laboratory tests that include blood coagulation, creatine kinase, electrolytes, urea, creatinine, and urine excretion are paramount for preventing and treating severe complications such as coagulopathy and rhabdomyolysis that could lead to renal failure.^{6,7} Our protocol for limb observation included immobilization with a splint without constricting bandaging, limb elevation after administration of antivenom serum, hourly examination of the extremity for oedema progression, ecchymosis, blistering, pain in passive muscle stretching, and paresthesia, in cases where the patient was old enough to communicate objectively. Devices to measure intercompartmental pressure were not available in our hospital. In all cases, antivenom serum for the most common viper species found in our region was administered without any adverse events. Reports on child envenomation in the southern European region are scarce in the literature. According to a systematic review by Chippaux, the annual incidence in Europe was 7992, with only 4 deaths per annum. Children and males were more affected, and immunotherapy was administered in one in three patients, with high geographical variability.⁸ In a large series by

Karabuva *et al.*,⁹ of 160 children and adolescents, 56% were bitten in the upper limb, and 7.5% developed compartment syndrome. In their series, only one child died after being bitten in the neck. In another report from Claudet *et al.*¹⁰ that included 83 children, being bitten on the upper extremity, intense initial pain, and high plasma glucose levels were associated with more severe envenomation. Small children seem to be more severely affected,¹¹ and high vigilance for the development of compartment syndrome is required beginning at 6-60 hours after the bite.¹² According to another large series of 219 patients, children were more susceptible to compartment syndrome than adults were⁴ and this finding should be considered when treating pediatric cases of viper bites.

Conclusion

Viper bites in children may occur in various situations indoors and outdoors. Caretakers should be aware of potential dangers during the warm summer period, as snakes may be hiding in places near households. In cases of snake envenomation, prompt management is paramount for a successful outcome. Supportive care is the mainstay of treatment, along with antivenom serum, but clinicians should be alert for the possibility of compartment syndrome. Early involvement of orthopedic surgeons in assessing the affected extremity is important for the timely recognition and management of compartment syndrome to maintain limb function and prevent serious adverse events.

Conflict of Interest

The authors declared no conflicts of interest.

References

1. 8 Venomous snakes found in Greece. Bird Watching HQ. <https://birdwatchinghq.com/venomous-snakes-of-greece/> (accessed 2024-08-04).
2. Red Book of Endangered Species of Greece; Legakis A, M. P., Ed.; Hellenic Zoological Society: Athens, 2009.
3. Frangides, C. Y.; Koulouras, V.; Kouni, S. N.; Tzortzatos, G. V.; Nikolaou, A.; Pneumaticsos, J.; Pierrakeas, C.; Niarchos, C.; Kounis, N. G.; Koutsoujannis, C. M. Snake Venom Poisoning in Greece. Experiences with 147 Cases. *Eur J Intern Med* **2006**, *17* (1), 24–27. <https://doi.org/10.1016/j.ejim.2005.10.001>.
4. Hermansen, M. N.; Krug, A. H.; Tjønnfjord, E.; Brabrand, M. Envenomation by the Common European Adder (*Vipera Berus*): A Case Series of 219 Patients. *Eur J Emerg Med* **2019**, *26* (5), 362–365. <https://doi.org/10.1097/MEJ.0000000000000577>.
5. Tunjić Pejak, D.; Neseć Adam, V.; Srzić, I. VENOMOUS SNAKEBITES IN CROATIA, CLINICAL PRESENTATION, DIAGNOSIS AND TREATMENT. *Acta Clin Croat* **2022**, *61* (Suppl 1), 59–66. <https://doi.org/10.20471/acc.2022.61.s1.10>.
6. Knudsen, C.; Jürgensen, J. A.; Føns, S.; Haack, A. M.; Friis, R. U. W.; Dam, S. H.; Bush, S. P.; White, J.; Laustsen, A. H. Snakebite Envenoming Diagnosis and Diagnostics. *Front Immunol* **2021**, *12*, 661457. <https://doi.org/10.3389/fimmu.2021.661457>.
7. Lavonas, E. J.; Ruha, A.-M.; Banner, W.; Bebart, V.; Bernstein, J. N.; Bush, S. P.; Kerns, W. P. 2nd; Richardson, W. H.; Seifert, S. A.; Tanen, D. A.; Curry, S. C.; Dart, R. C. Unified Treatment Algorithm for the Management of Crotaline Snakebite in the United States: Results of an Evidence-Informed Consensus Workshop. *BMC Emerg Med* **2011**, *11*, 2. <https://doi.org/10.1186/1471-227X-11-2>.
8. Chippaux, J.-P. Epidemiology of Snakebites in Europe: A Systematic Review of the Literature. *Toxicon* **2012**, *59* (1), 86–99. <https://doi.org/10.1016/j.toxicon.2011.10.008>.
9. Karabuva, S.; Vrkić, I.; Brizić, I.; Ivić, I.; Lukšić, B. Venomous Snakebites in Children in Southern Croatia. *Toxicon* **2016**, *112*, 8–15. <https://doi.org/10.1016/j.toxicon.2016.08.008>.

- org/10.1016/j.toxicon.2016.01.057.
10. Claudet, I.; Grouteau, E.; Cordier, L.; Franchitto, N.; Bréhin, C. Hyperglycemia Is a Risk Factor for High-Grade Envenomations after European Viper Bites (*Vipera Spp.*) in Children. *Clin Toxicol (Phila)* **2016**, 54 (1), 34–39. <https://doi.org/10.3109/15563650.2015.1113542>.
 11. Grönlund, J.; Vuori, A.; Nieminen, S. Adder Bites. A Report of 68 Cases. *Scandinavian Journal of Surgery* **2003**, 92 (2), 171–174. <https://doi.org/10.1177/145749690309200211>.
 12. Cawrse, N. H.; Palmer, J. H.; Hayes, C.; Inglefield, C. J. A Snake in the Clinical Grass: Late Compartment Syndrome in a Child Bitten by an Adder. *Br J Plast Surg* **2002**, 55 (5), 434–435. <https://doi.org/https://doi.org/10.1054/bjps.2002.3888>.



Cite this
paper as

Chatziravdeli V, Arapoglou D, Gekas C, Kalaitzis V, Dionellis P. Orthopedic involvement in viper bite in children in Greece. Report of four cases. AOTH. 2025; 76(3):19-25.

DOI

<https://doi.org/10.69133/aoth.v76i3.521>