

Spinal Surgery in Patients with Parkinson's Disease

George Sapkas¹, Stamatios Papadakis², Michael Papadakis³

¹Professor of Orthopaedics Orthopaedic Department Metropolitan Hospital, Neo Faliron – Athens – Greece

²Director of the 2nd Orthopaedic Department K.A.T. Hospital, Athens – Greece

³Orthopaedic Surgeon Orthopaedic Department Metropolitan Hospital, Neo Faliron-Athens-Greece

ABSTRACT

Parkinson's Disease (PD) is a degenerative disorder of the central nervous system. Recent advances in the treatment of PD have improved the life expectancy and quality of life of patients. Spinal surgery improves deformities of the spine in these patients. Moreover, a lot of studies have shown that operative treatment of various diseases of the spine in PD patients is associated with a large percentage of post-operative complications, that make a surgery revision necessary.

The purpose of the present review article is to assess the number and type of complications of spine surgery in PD patients and determine whether the presence of PD predisposes patients to a higher rate of such complications.

Key Words: Parkinson Disease; Spinal Surgery; Complications in Parkinson Disease
Short/running Title: Post-operate Spinal Complications

Introduction

Parkinson's disease (PD) is a progressive degenerative disorder of the central nervous system, affecting the substantia nigra in the midbrain and the dopaminergic cells of the substantial nigra. Parkinson's disease follows Alzheimer's disease and represents the second most common neuro-degenerative disease. Its prevalence increases exponentially with age, being estimated at 1,5% of the population over 60 years in Europe (1). Recent advances in the treatment of Parkinson's disease have improved the life expectancy and quality of life of patients. It none-

theless remains a debilitating disease, with those affected becoming increasingly incapable to perform their daily activities. Patients with PD have a wide spectrum of symptoms: Bradykinesia, tremor, rigidity, flexion of the trunk, hip and knees. This disorder leads to abnormal loads of the spine (1,2). Spinal surgery improves deformity of the spine in these patients. Moreover, a lot of studies have shown that surgical treatment of various diseases of the spine in PD patients is associated with a large percentage of post-operative complications that make a revision surgery necessary (3,4,5). PD patients are also affect-

CORRESPONDING
AUTHOR,
GUARANTOR

Professor George Sapkas
Koumarias 16-B, EKALI - T.K. 14578 ATHENS – GREECE
Cell : 6932.226.746 E-Mail: gsapkas1@gmail.com

ed by spinal disorders and as the population ages, are expected to represent an increasingly substantial proportion of patients requiring spinal surgery. The typical parkinsonian posture is flexion of the trunk, hip and knees, thus shifting the center of gravity and subjecting the patient's spine to abnormal loads. In fact, the stooped posture that is so characteristic of the disease as to have been described by James Parkinson himself in 1817, probably predisposes to an increased rate of spinal degeneration, although this remains to be confirmed. Nonetheless, degenerative conditions and particularly degenerative scoliosis have been found to be more frequent in PD patients than their age-matched counterparts (2,6). Furthermore, PD is also associated with an array of postural deformities besides the typical abnormal posture such as camptocormia (marked forward flexion of the thoracolumbar spine), (Figure 1a,b), Pisa syndrome (lateral flexion and axial rotation of the trunk), anterocollis (dropped head syndrome) and degenerative scoliosis (2,4). In addition patients with PD are fragile, having a high rate of falls and osteoporosis (6,7,8). The purpose of this review study is to assess the number and type of complications of spine surgery in PD patients and determine whether the presence of PD predisposes patients to a higher rate of such complications.

Previous studies on spinal surgery in PD patients are sparse and of retrospective design; they all have in common an exceptionally high rate of complications (Table 1).

Surgical complications can be divided in early and late ones. Early complications related to Parkinson systemic impairment are seen in the immediate post-operative period. In a recently published multicenter study **Babat et al**, (7) retrospectively studied 14 patients with PD who had spinal surgery. They noted a high rate of surgical revision (86%). They suggested as primary causes of this high revision rate, the segmental instability at the level of surgery and kyphosis at the junctional levels. This is in accordance with the findings of **Sapkas et al** (11). In their study the revision rate was 57,1%. **Kaspar et al**, (12) assessed the post-operative complications of all types of spinal surgeries in PD patients and found a revision rate of 4/24. They concluded that

the complication rate in PD patients was comparable to that of normal population. Furthermore, the functional damage and symptoms directly related to the spinal disease had been masked by PD, causing diagnostic difficulties, especially for cervical arthritic myelopathy.

In a recently published multicentric study, 42% of 48 patients who underwent a long fusion from the upper thoracic spine to the sacrum or pelvis required a revision surgery. The authors pointed out that the main complication were due to pseudarthrosis and junctional kyphosis (16). In a study by **Sapkas et al**, (11) it was pointed-out that close follow-up in PD patients with a complication is crucial. Their opinion is that the restoration of sagittal balance is always fundamental. But specially in PD patients it is probable even more important. **Koller et al**, (14) also recommend adding fusion to any decompression surgery and extending fusions as much as necessary into the thoracic spine or into the pelvis using S2 or Iliac Screws. Long fusion were studied in the paper from **Bourghli et al** (15), wherein 12 patients with PD underwent posterior fusion from T2 to the sacrum for various disorders (Figure 2a,b,c,d,e,f). Revision surgery was performed in 6 patients, 3 for hardware failure, 2 for proximal junctional kyphosis and one for epidural hematoma.

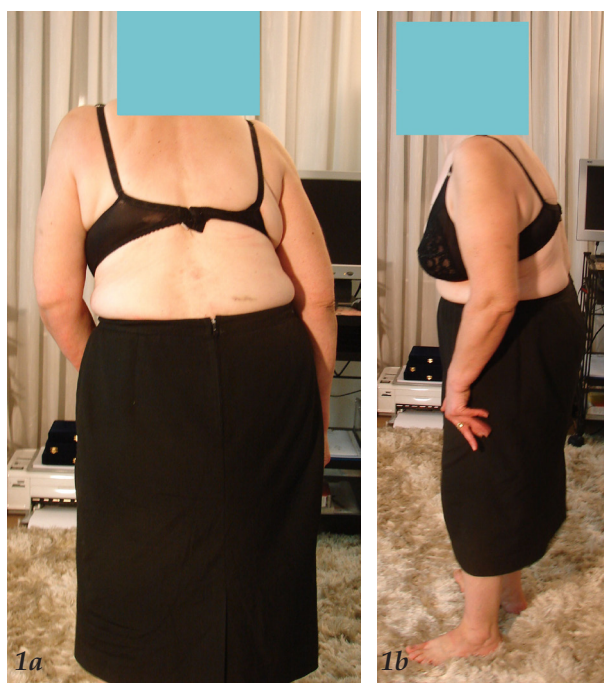The most common complication reported is instability at the level above the spondylodesia due to adjacent spinal segment degeneration, screw pull-out, flat back and camptocormia (14,15,16). In a study by **Sapkas et al**, (11), 20 out of 21 patients had worsening of their stability within three years post-operatively. One of the patients who initially treated with fusion from L2 to S1 six months post-operated, developed post-junctional kyphosis. He refused further surgical treatment and he presented three years later with a flat-back. Only one patient who was treated initially for lumbar stenosis, had no complication 8 years post-operatively. Adjacent segment degeneration with proximal junctional kyphosis (PJK) has been widely described after posterior procedures. The etiology of PJK is probably due to various factors among these patients, including the iatrogenic effect of the fusion, the age-related osteoporosis, disc degeneration and the neuromuscular disease. **Scenama et al**,

TABLE 1.

Studies about PD patients and rate of revision spinal surgery

| AUTHOR | PATIENTS | REVISION RATE | REMARKS |
|-----------------|----------|---------------|---|
| Bouyer et al | 40 | 42% | Mechanical complications |
| Schroeder et al | 96 | 20.8% | Early complications relative to infection |
| Babat et al | 14 | 85.7% | Technical complications |
| Koller et al | 23 | 33.3% | High rate of infection |
| Sarkiss et al | 95 | 45% | N/A |
| Scenema et al | 19 | 0% | Follow-up 2 years only |
| Bourghli et al | 12 | 50% | Long spinal fusion T2-sacrum |
| Moon et al | 20 | N/A | Compared to no PD patients |
| Wadia et al | 2 | 50% | Two cases of camptocormia |
| Kaspar et al | 24 | 21% | Mean nineteen months follow-up |

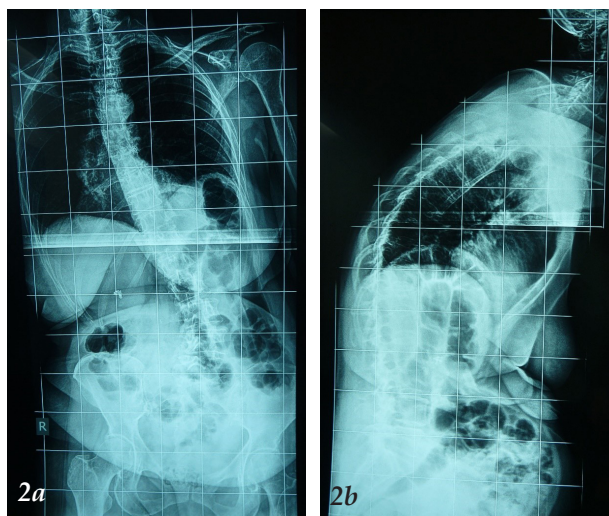
(17) noticed that there was no association between C7 plumbline and last follow-up in the ODI (Oswestry Disability Index). Bourghli et al, (15) and Koller et al, (14) insisted on the fact that if spinal surgery is indicated in patients with PD, the restoration of spinopelvic balance with focus on lumbar lordosis and global sagittal alignment is required. Statistical analysis revealed that patients with notable post-operative or follow-up sagittal imbalance (sagittal vertical axis (SVA)>10cm) had a significantly increased rate of revision surgery performed or scheduled. Patients who underwent surgery were more likely to have post-operative or final sagittal imbalance (15,17). In a study by Koller et al, (14), 23 PD patients suffering from various spinal disorders, were surgically treated. Fifty two percent (52%) of the patients presented with a complication and 33% of them had revision surgery. However, a high rate of satisfaction among patients reaching 74% of the patients was satisfied with the clinical results. The authors stated that restoration of the sagittal balance is crucial in order to achieve successful results. This observation can be attributed to the fact that PD patients do not require the same degree of restoration of the sagittal alignment, in order



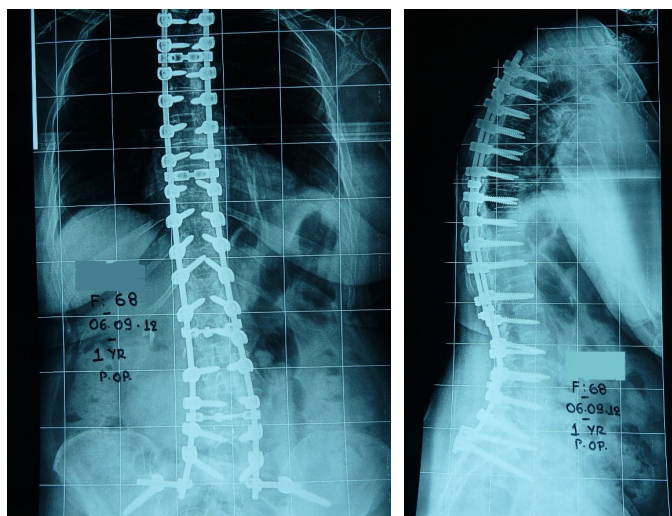
Figures 1a, 1b: Anteroposterior¹ and lateral 2 photograph of the 65 years old female patient, who is submitted to operative treatment for the correction of her spinal deformity. It is obvious the camptocormia of her body. In addition she has flexed her hips and knees in an effort to improve the stature of the unbalanced body.

to enable a line of sight safe enough to walk and also they have reduced mobility and lower functional daily activities than the general population. In a study by Torsney et al, (18) the authors found that osteoporosis was a risk factor of a ratio of 2,61 in PD patients in comparison with healthy controls. Furthermore, a lower bone mineral density (BMD) and an increased fracture risk is also reported. Vitamin D deficiency and antiparkinsonian drugs can be involved in the reduced BMD (20). Schroeder et al, (20) in light of their findings recommend that when treating a patient with PD, the most critical point of discrimination in the severity of the disease. Patients with a modified Hoehn and Yahr (19) stage of >3, surgery should be performed only in cases with myelopathy due to high complications risk. However, in stage <3, other comorbidities of the patients should be evaluated. If no major risk factors are present, then the patient's spine pathological condition should be evaluated. Overall, the surgical risk for the patient is higher than that for the general population (22). Poor clinical outcome is related to natural progression of the pathology (13,6). However, risk factors should be considered in selected patients who might benefit from the surgical intervention. Sarkiss et al, (22) showed that poor outcome was associated to: older age, thoracolumbar kyphosis, osteoarthritis of the hip and increasing level of camptocormia. Risk factors related to the surgery itself, were post-operative SVA greater than 5 cm, inadequate sacropelvic fixation and poor fusion level selection. Another review by Galbusera et al, (23) concluded that poor outcomes related to high rate of complication and revisions are usual, but majority of patients are satisfied with their new quality of life. In addition to low bone quality, postural instability, motor disorders and autonomous nervous system dysfunction are playing an important role of a fracture risk after a fall. On the other hand, is worth to note that all of the patients are of progressive age and they are presented often with comorbidities (25,26). This fact is highlighted in a study by Baker et al, (26), who reported an increased risk of cardiac, pulmonary, hemorrhagic complications in PD patients, in contrast to non-PD patients who underwent spinal surgery (27). According to Vaserman et al, (3) patients with PD have high osteoporosis

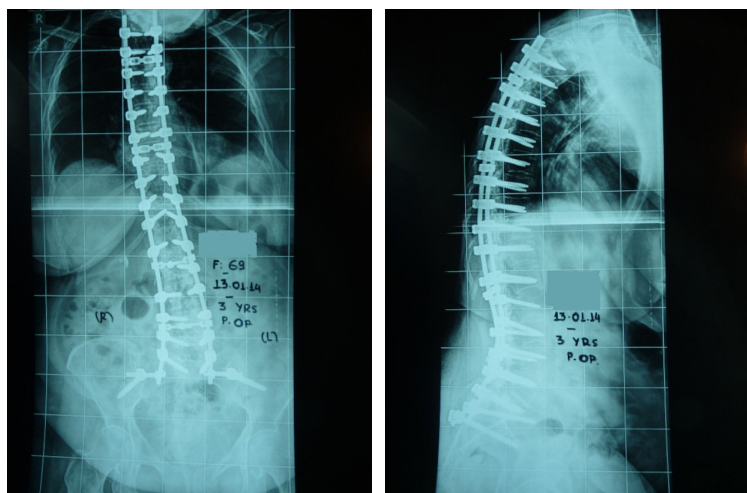
rate. In combination with the muscular dysfunction, osteoporosis contributes to fusion failure (27,28). In such cases with osteoporotic bones and loss of function of the spinal extensor muscles, directly related to the disease and the age-associated fatty degeneration (steatosis) long spondylodesia by a posterior approach is indicated. Nakashima et al, (8) report on 3 patients with vertebral body collapse that underwent circumferential fusion. All 3 had a marked progression of kyphosis, however no further operations were performed. Peek et al, (16) published a case report of a patient treated for PD associated camptocormia. Due to recurring hardware failures, he required multiple re-operations, lengthy hospitalizations and prolonged immobilization in orthoses and hip spicas. Upadhyaya et al, (6) mention two PD patients that underwent spinal fusion. One was complicated by deep infection; the other underwent revision surgery due to pseudarthrosis and screw pull-out. Wadia et al, (28) report two cases of camptocormia corrected with spinal fusion. The first patient had to undergo two revisions within a year, of hi-index procedure due to hardware failure. The other also experienced hardware failure but was deferred from revision surgery due to poor general health, in a study from Korea. Moon et al, (9) report their results on 20 patients with PD that underwent lumbar fusion. There was no statistically significant difference between the pre-operative and post-operative visual analogue scale (VAS) scores in their cohort. Likewise, there were 4 instances of pseudarthrosis and one instance of screw pull-out. The authors state that their low rate of complications, in comparison to other studies of the same sort, is probably due to the short segment fusions that were performed in their cohort (14 one-level, 5 two-level and 1 three-level). As the population ages and with improved results in medical and surgical treatments, increasing numbers of PD patients will require spine surgery. However, it is becoming increasingly clear that this subgroup of patients is at an elevated risk of complications and adverse outcomes. Indeed, the collective experience so far is that multiple re-operations have been necessary to achieve a satisfactory outcome in patients who already have to cope with a debilitating disorder. Being older, PD patients are expected to have decreased



Figures 2a,2b: Anterior-posterior and Lateral x-Rays of the spine in a standing position. His remarkable @ Lateral Bending of the spine and the subluxation of the 4th over the 5th lumbar vertebra.



Figures 2c,2d: First post-operative x-Rays of the patient. The spinal deformity has been corrected and stabilized with Spondylodesia. The spondylodesia is extended from the 3rd thoracic vertebra to the sacrum and iliac bones. Intervertebral cages have been applied to the L4-L5 and L5-S1 intervertebral space.



Figures 2e,2f: Three years post-operative x-Rays of the spine. The implants are intact and in their place, without loosening or with-drawing of the screws, apart perhaps loosening of the right iliac screw. It is observed mild swift- ing of the body to the right and proximal junctional kyphosis. The patient is however very satisfied, because her mobilization and stance have improved a lot, especially following the neurosurgical operation that it was performed in the brain for the Parkinson Disease.


bone mass. In addition, the very nature of the symptoms of PD forces patients to inactivity. This in turn results in disuse osteoporosis. Indeed, it has been demonstrated that PD patients have decreased bone mass when compared to age matched controls (12,13). Therefore, in addition to muscular dysfunction, poor bone quality further contributes to implant and fusion failure. The muscular dysfunction that results from PD not only makes the posterior tension band weak, but also makes spinal adjustment in areas adjacent to surgical fusions unfeasible. Myopathies of

different kinds are quite common in PD patients (14,16) but even in the absence of a frank myopathy, the flexed posture that these patients assume will result in excessive loading of any implant. Reports from orthopaedic and other surgical literature have also shown that PD patients are more likely to develop common complications such as pneumonia, confusion, urinary tract infections and decubitus ulcers (17). Surgical site infections are also quite common, as described in the series of Babat et al (7) and Koller et al (14).

The Management of spinal conditions, in patients with PD complex because of poor muscular supporting capability, diminished bone mineral density, motor control dysfunction in addition to the increased risk of surgical complications and the presence of comorbidities in this aged population, it is an extremely demanding case. In general, before considering surgery, parkinsonian symptoms should be controlled as much as possible, whereupon a consultation with a neurologist is essential. Bone mineral density should also be evaluated and appropriately corrected. The patient should be monitored closely for the development of post-operative complications and rehabilitation should commence as early as possible(18) For spinal surgery in particular, careful pre-operative planning for proper fusion level selection and restoration of sagittal balance is always fundamental (11,14,15,21), but in PD patients it is probably even more crucial. Sapkas et al (11). Koller et al (14) also recommend adding fusion to any decompression surgery and extending fusions as much as necessary into the thoracic spine and into the pelvis using S2 or iliac screws.

Conclusions

As life expectancy in patients with PD is increased more and patients undergo spinal surgery mainly due to kyphosis or other deformities, these surgeries have a high rate of complications. Therefore, careful pre-operative planning needs to be implemented for the correct selection of patients and the level of the fusion. Furthermore, it is necessary to maintain a close post-operative follow-up despite the fact that the results are disappointing and a revision surgery is often needed. As the evidence amasses, it is becoming increasingly clear that PD patients are a high risk subgroup. Although poor clinical outcomes related to high rate of complications and revisions are frequently reported, most of the patients are satisfied from

surgery and report better quality of life compared to pre-operative period. Spinal imbalance in PD patients responds poorly to dop-aminergic treatment and may even be aggravated by it. Neurosurgical treatment by deep brain stimulation of the subthalamic nucleus, that strongly reduces the symptoms it is strongly suggested. However there are very strict inclusion criteria for this treatment and it is reserved for a particular category of patients. For patients with osteoporotic bones facing the loss of function of the spinal extensor muscles directly related to this disease and to age associated fatty degeneration (steatosis), is proposed long Spondylodesia by a posterior approach, extending from T2 to the sacrum. Early preventive physical therapy may be able to delay the onset of postural disorders, but will not prevent their progression. 

Abbreviations List

| | |
|------|--------------------------------|
| PD= | Parkinson Disease |
| BMD= | Bone Mineral Density |
| PJK= | Proximal Junctional Kyphosis |
| ODI= | Oswestry Disability Index |
| SVA= | Sagittal Vertical Axis |
| ASD= | Adjacent Segment Disease |
| VCF= | Vertebral Compression Fracture |

Highlights

Spinal disorders in PD patients are often
Spinal Surgeries in PD patients present numerous complications
PD patients have high rate of revision surgeries.

Acknowledgements

Not Applicable

Conflicts of Interest

The authors declare that they have no conflicts of Interest.

REFERENCES

1. Von Campenhausen S, Bornschein B, Wick R, Botzef K, Sampaio C, Poewe W, Oertel W, Siebert U, Berger K, Dode R. Prevalence and incidence of Parkinson's Disease in Europe. *Eur Neurol*. 2005;15:473-490. <https://doi.org/10.1016/j.euroneuro.2005.04.007>
2. Doherty KM, Van de Warrenburg BP, Peralta MC, Silveira-Moriyama L, Azulay JP, Gershanik O, Bloem BR. Postural deformities in Parkinson's disease. *Lancet Neurol*. 2011;10:538-549. doi:10.1016/S1474-3. 3.
3. Vasserman N. Parkinson's disease and osteoporosis. *Joint Bone Spine*. 2005;72:484-488. <https://doi.org/10.1016/j.jbspin.2004.04.012>. 4422(11)70067
4. Invernizzi M, Carda S, Viscontini GS, Cisari C. Osteoporosis in Parkinson's disease. *Parkinsonism Related Disorder*. 2009;15:
5. Schabitz WR, Glatz K, Schuhan C, Berger C, Schwanner M, Hartmann M, Goebel HH, Meinck HM. Severe forward flexion of the trunk in Parkinson's disease focal myopathy of the paraspinal muscles mimicking camptocormia. *Mov Disord*. 2003;18:408414.346. <https://doi.org/10.1016/j.parkdis.2009.02.009>.
6. Upadhyaya CD, Starr PA, Mummaneni PV. Spinal deformity and Parkinson disease a treatment algorithm. *Neurosurg Focus*. 2010;28:1-7. <https://doi.org/10.3171/2010.1.Focus09288>. <https://doi.org/10.1002/mds.10385>.
7. Babat LB, McLain RF, Bingaman W, Kalfas I, Young P, Rufo-Smith C. Spinal surgery in patients with Parkinson's disease construct failure and progressive deformity. *Spine (Phila Pa 1976)*. 2004;29:2006-2012. Doi:10.1097/01.brs.0000138306.02425.21.
8. Nakashima H, Yukawa Y, Ito K, Machino M, Ishiguro N, Kato F. Combined posteroanterior surgery for osteoporotic delayed vertebral fracture and neural deficit in patients with Parkinson's disease. *Nagoya J Med Sci*. 2014 Aug; 76(3-4):307-314.
9. Moon SH, Lee HM, Chun HJ, Kang MS, Kim HS, Park JO, Chong HS, Sohn JS. Surgical outcome of lumbar fusion surgery in patients with Parkinson disease. *J Spinal Disorder Tech*. 2011;25:351-5.
10. Benatru I, Vaugoyeau M, Azulay JP. Postural disorders in Parkinson's disease. *Neurophysiol Clin*. 2008;38:459-465. doi:10.1016 / j. neucli. 2008.07.006.
11. Sapkas G, Lykomitros V, Soultanis K, Papadopoulos EC, Papadakis M. Spinal Surgery in patients with Parkinson's Disease. Unsatisfactory results, failure and disappointment. *Open Orthop J*. 2014;8:264-267. Doi:10.2174/1874325001408010264.
12. Kaspar S, Riley L, Cohen D. Spine surgery in Parkinson's. *Journal of Bone and Joint Surgery*. 2005;87:292-298.
13. Puvanesarajah V, Jain A, Qureshi R, Carstensen E, Tyger R, Hassanzadeh H. Elective thoracolumbar spine fusion surgery in patients with Parkinson disease. *World Neurosurg*. 2016;913.
14. Koller H, Acosta F, Zenner J, Ferraris L, Hitzl W, Meier O, Ondra S, Koski T, Schmidt R. Spinal surgery in patients with Parkinson's disease experiences with the challenges posed by sagittal imbalance and the Parkinson's spine. *Eur Spine J*. 2010;19:1785-1794. Doi 10.1007/s00586-010-1405-y. 6:267-231. <https://doi.org/10.1016/j.wneu.2016.09.014>.
15. Bourghli A, Guerin P, Vital JM, Aurouer N, Luc S, Olivier Gille O, Vincent Pointillart V, Obeid I. Posterior spinal fusion from T2 to the sacrum for the management of major deformities in patients with Parkinson disease: A retrospective review with analysis of complications. *J Spinal Disord Tech*. 2012;25:53-60. Doi: 10.1097/bsd.0b013e3182496670.
16. Peek AC, Quinn N, Casey AT, Etherington G. Thoracolumbar spinal fixation for camptocormia in Parkinson's disease. *J Neurol Neurosurg Psychiatry*. 2009;80:1275-8. <http://dx.doi.org/10.1136/jnnp.2008.152736>
17. Scenama C, Mangone G, Bonaccorsi R, Pascal-Moussellard H. Functional results and patient satisfaction
18. Torsney KM, Noyve AJ, Bestwick J, Dobson R, Lees A. Bone health in Parkinson's disease: a systematic review and meta-analysis. *J Neurol Neurosurg Psychiatry*. 2014;85:1159-1166. <https://dx.doi.org/10.1136/jnnp-2013-307307>
19. Hoehn MM, Yahr M. Parkinsonism: onset, progression and mortality. *Neurology*. 1967;17:427-442. doi:10.1212/wnl.17.5.427
20. Schroeder JE, Hughes A, Sama A, Weinstein J, Kaplan L, Cammisa F, Girardi F. Lumbar spine surgery in patients with Parkinson disease. *J Bone Joint Surg Am*. 2015;97:1661-1666. doi:10.2106/JBJS.N. 01049.

21. Bouyer B, Scenama C, Roussouly P, Laouissat F, Obeid I, Boissiere L, Parent FH, Schuller S, Steib JP, Pascal-Mousellard H, Guigui P, Wolff S, Guillaume R. Evolution and complications after surgery for spine deformation in patients with Parkinson's disease. *Orthop Traumatol Surg Res*. 2017;103:517-522. <https://doi.org/10.1016/j.otsr.2016.12.04>.
22. Sarkiss CA, Fogg GA, Sjoerlj B, Cho SK, Caridi JM. To operate or not A literature review of surgical outcomes in 95 patients with Parkinson's disease undergoing spine surgery. *Clin NEUROL Neurosurg* 2015;134:122-125. <https://doi.org/10-1016/j.clineuro.2015.04.022>.
23. Galbusera F, Tito B, Stucovitz E, Martini C, Ismael Aguirre MF, Berjano P, Lamartina C. Surgical treatment of spinal disorders in Parkinson disease. *European Spine Journal*. 2018;27:101-108.
24. Gerlach OH, Winogrodzka A, Weber WE. Clinical problems in the hospitalized Parkinson's disease patient systematic review. *Mov.Disord*. 2011;26:197-208. doi:10.1002/mds.23449.
25. Zuckerman LM. Parkinson's disease and the Orthopaedic patient. *J Am Acad Orthop.Surg*. 2009;17:48-55. Doi: 10-5435/00124635-200901000-00007.
26. Baker J, McClelland S, Robert H, Bess S. Management of Spinal Conditions in patients with Parkinson's disease. *Journal of the Americal Academy of Orthopaedic Surgeons*. 2017;25:157-165.doi: 10.5435/JAAOS-D-16-00627.
27. Gdynia HJ, Sperfeld AD, Unrath A, Ludolph A, Sabolek M, Storch A, Kassubeket J. Histopathological analysis of skeletal muscle in patients with Parkinson's disease and dropped head'/bend' spine syndrome. *Parkinsonism Relat Disord* 2009;15:633-639. Doi.10.1016/j.parkeldis.2009.06.003
28. Wadia PM, Tan G, Munhoz RP, Fox S, Lewis S, Lang A. Surgical correction of kyphosis in patients with camptocormia due to Parkinson's disease a retrospective evaluation. *J. Neurol Neurosurg Psychiatry* 2011;82:364-368. <https://dx.doi.org/10.1136/jnnp.2009.176198>.

READY - MADE
CITATION

Sapkas G, Papadakis St, Papadakis M. Spinal Surgery in Patients with Parkinson's Disease. *Acta Orthop Trauma Hell* 2021; 72(1): 58-65.