

# The effect of patient positioning on the relative positioning of the aorta to the thoracic spine in patients with scoliosis.

Plataniotis N<sup>1,2</sup>, Evangelopoulos DS<sup>1</sup>, Bakalakos M<sup>1</sup>, Vlamis J<sup>1</sup>, Pneumáticos S<sup>1</sup>

<sup>1</sup>3rd Department of Orthopaedic Surgery, National & Kapodistrian University of Athens,  
KAT Hospital, Athens, Greece

<sup>2</sup>Department of Radiology, KAT Hospital, Athens, Greece

## ABSTRACT

A serious, although rare, complication of thoracic spinal surgery is iatrogenic vascular injury of the aorta. The position of the thoracic aorta relative to the spine is crucial in the preoperative planning of thoracic spine surgery, regardless of the surgical approach used. We performed this study in order to evaluate the displacement of the aorta relative to the spine (levels T4 to T12) in patients with scoliotic deformity in supine, prone and prone with padding position. Twenty patients underwent CT scan of the thoracic spine and the minimum distance from the entry point of the left pedicle screw to the thoracic aortic wall was calculated. Statistical analysis revealed significant difference in this distance between the three different patient positions per level. In particular, aortic wall tends to be closer to the left pedicle screw with the patient in prone with padding position. Thus, our findings may be useful in aortic displacement estimation and allow the surgeon to decide on the appropriate surgical approach aiming at the safe positioning of pedicle screws.

**Keywords:** spine surgery; surgical approach; thoracic aorta,

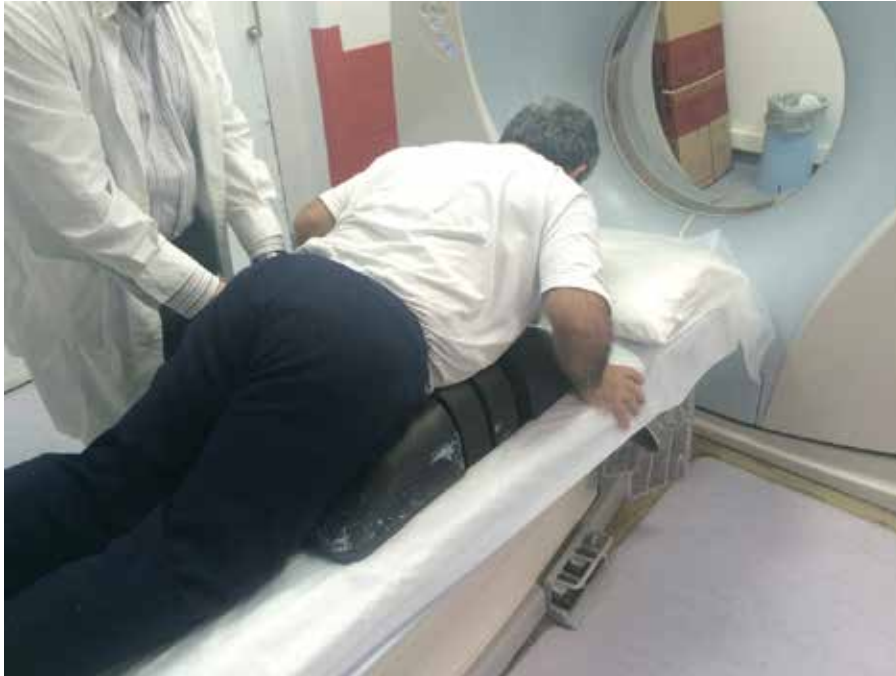## Introduction

Thoracic spinal surgery accounts for 5-10% of all spinal surgeries, with more frequent causes being fractures, degenerative stenosis, kyphoscoliotic deformities, and intervertebral disc herniation. Surgeons dealing with this field have developed fusion techniques for trauma and spinal deformity correction. The most commonly used approach is posterior, while anterolateral approach

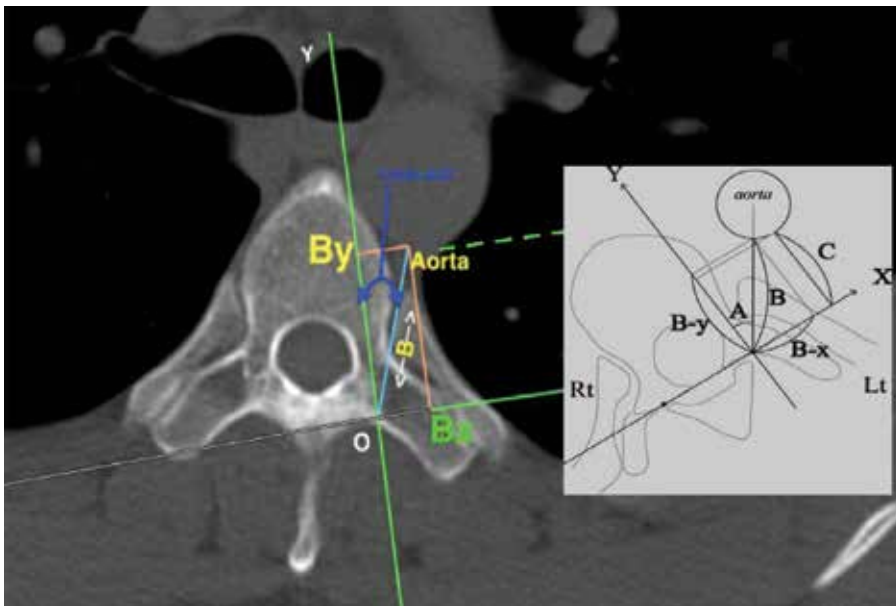
remains a possible option during thoracic spinal surgery [1]. Moreover, new percutaneously and endoscopically assisted fusion techniques have been developed, which offer many benefits, including less pain and shorter rehabilitation time, to patients over traditional surgeries [2]. A possible and serious complication is iatrogenic vascular injury either during pedicle screw placement or secondary relaxation and migration of the

CORRESPONDING  
AUTHOR,  
GUARANTOR

**Dimitrios Stergios Evangelopoulos**  
3rd Dpt of Orthopaedic Surgery, NKUA  
+30-6932214079  
ds.evangelopoulos@gmail.com



**Fig. 1:** Patient in prone with padding surgical position in an effort to reproduce surgical positioning during posterior thoracic spinal surgery.



**Fig. 2:** Axial view of the vertebrae. The reference point 0 is defined as the point of pedicular screw entry along the pedicular axial line (axis y). The minimum distance to the aortic edge B is drawn with the respective Bx - By projections defined on axis x and y.

screw [3,4]. Thus, the position of the thoracic aorta relative to the spine is crucial in the preoperative planning of thoracic spine surgery, regardless of the surgical approach used. The purpose of this study was to evaluate the displacement of the aorta relative to the spine (levels T4 to T12) in patients with scoliotic deformity in supine, prone and prone with padding position.

#### Materials and Methods

Patients who were examined in the outpatient clinic of our department with a scoliotic deformity of >15 degrees Cobb angle and able to give informed consent were eligible for inclusion in the study. All patients underwent CT scan of the thoracic spine with slice thickness of 5 mm. All CT scans were performed in the standard supine, as well as in, the prone and prone with padding positions in an effort to reproduce surgical positioning during posterior thoracic

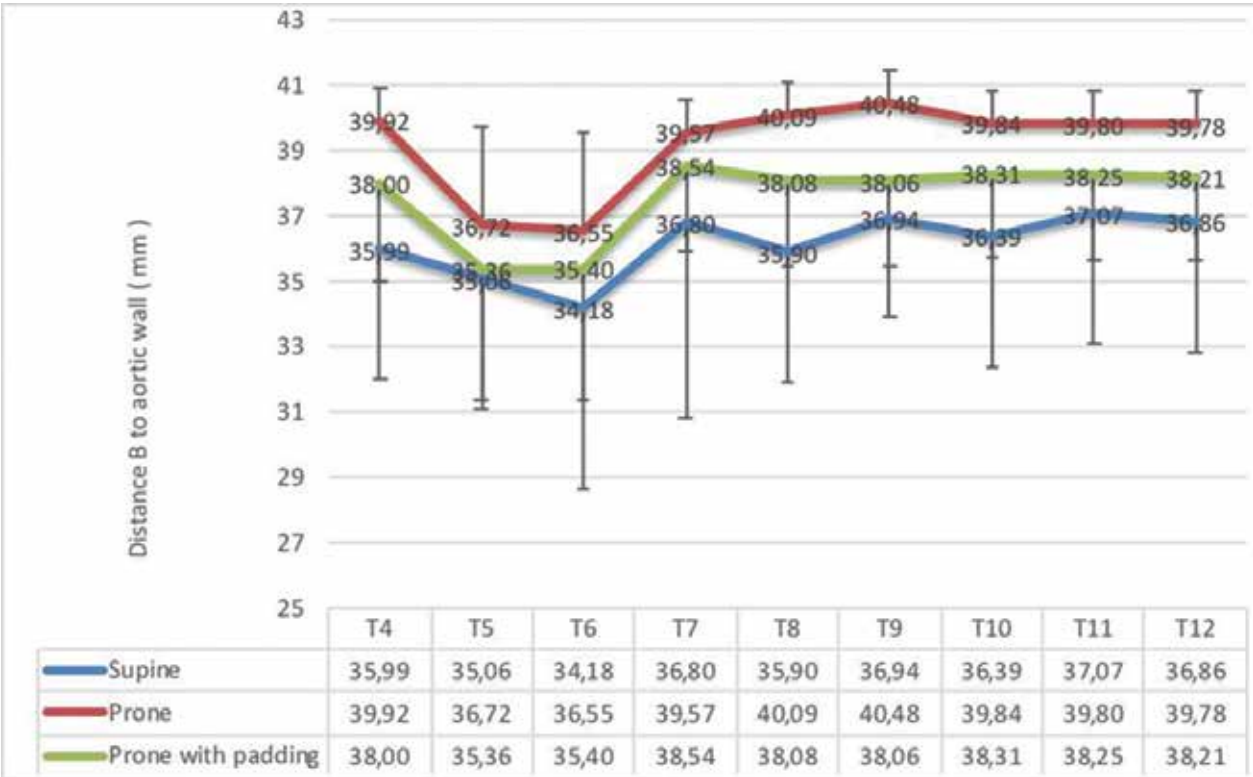


Fig. 3: Mean B values across all vertebrae in the three different patient positions.

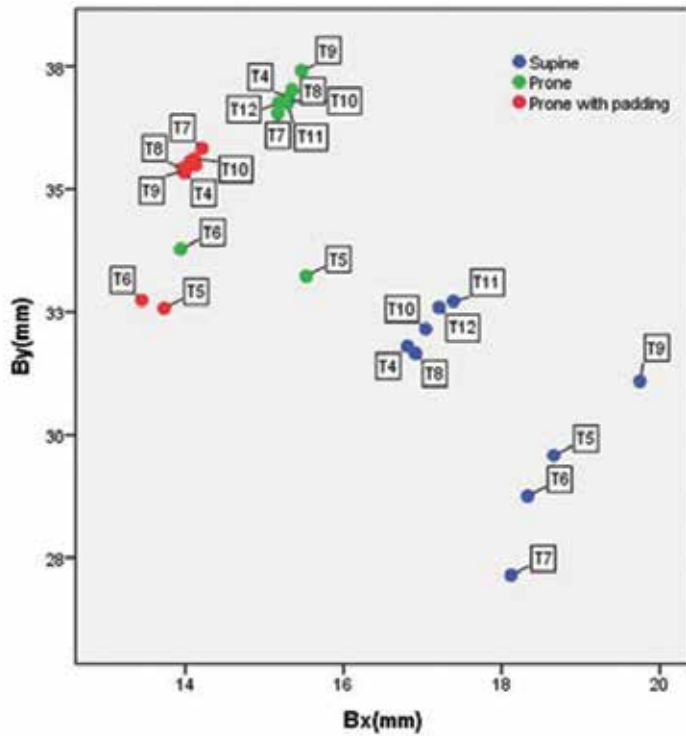


Fig. 4: Scatter plot where a tendency of the aorta to shift medially and anteriorly in relation to the thoracic spine, while patient changes from supine in prone and prone with padding position, is depicted.

**TABLE 1.** Mean distance B, Bx, By from pedicle entry point O to the aortic wall, across thoracic levels T4-12, with SD's, F-Values and P-values respectively

		Supine position		Prone position		Prone with padding position		F-value	p-value
Distance B	T4	35.99	3.98	39.92	2.92	38.00	1.05	47.05	<0.001
	T5	35.06	4.3	36.72	4.47	35.36	3.02	10.38	<0.001
	T6	34.18	5.5	36.55	4.05	35.40	2.64	8.26	0.004
	T7	32.78	5.85	39.57	2.44	38.54	0.72	186.51	<0.001
	T8	35.90	3.80	40.09	2.64	38.08	1.21	113.68	<0.001
	T9	36.94	3.01	40.48	2.65	38.06	0.89	114.06	<0.001
	T10	36.39	3.90	39.84	2.70	38.31	1.05	75.48	<0.001
	T11	37.07	3.62	39.80	2.96	38.25	1.00	51.84	<0.001
	T12	36.86	3.43	39.78	2.45	38.21	0.95	66.06	<0.001
Distance Bx	T4	16.81	1.94	15.31	1.23	13.99	0.45	227.47	<0.001
	T5	18.66	3.1	15.53	2.37	13.73	1.25	223.53	<0.001
	T6	18.33	3.50	13.94	1.54	13.45	1.10	279.48	<0.001
	T7	18.12	4.13	15.17	1.02	14.21	0.31	134.78	<0.001
	T8	16.91	1.84	15.35	1.10	13.97	0.46	266.10	<0.001
	T9	19.75	3.02	15.47	1.10	14.00	0.40	499.71	<0.001
	T10	17.04	1.93	15.26	1.11	14.11	0.45	247.56	<0.001
	T11	17.39	1.95	15.29	1.26	14.06	0.41	315.92	<0.001
	T12	17.21	1.68	15.18	1.00	14.13	0.39	351.65	<0.001
Distance By	T4	31.81	3.56	36.87	2.71	35.33	1.00	198.41	<0.001
	T5	29.58	3.83	33.23	4.13	32.57	2.84	63.44	<0.001
	T6	28.75	4.91	33.78	3.79	32.74	2.46	103.62	<0.001
	T7	27.14	5.20	36.54	2.26	35.83	0.68	480.37	<0.001
	T8	31.66	3.39	37.02	2.46	35.42	1.15	238.32	<0.001
	T9	31.09	2.78	37.41	2.45	35.38	0.85	427.33	<0.001
	T10	32.15	3.45	36.79	2.50	35.62	1.00	182.48	<0.001
	T11	32.72	3.13	36.75	2.73	35.57	0.90	147.98	<0.001
	T12	32.59	3.08	36.76	2.28	35.49	0.86	170.61	<0.001

spinal surgery (**Figure 1**). Axial images of the vertebrae, in which both vertebral pedicles are depicted, were obtained for measurements from T4 to T12 level in supine, prone and prone with padding position. The entry point of the left pedicle screw was selected as the point where the left transverse process intersects with the longitudinal axis of the left screw, and was designated as the reference point 0. The y-axis was defined as the front axis of the left screw and the x-axis as the perpendicular to y-axis passing through the reference point 0. Finally, the following parameters were measured in the axial tomography: 1) minimum distance B from the entry point 0 to the thoracic aortic wall and 2) projections Bx, By as defined by the x and y axes, representing the lateral and anterior-posterior displacement of the aortic wall relative to the left pedicle entry point O (**Figure 2**). All measurements were performed by two independent observers and mean values were calculated using Vitrea 2 Imaging Software. Intraobserver and interobserver variability were examined using the intra-class correlation coefficient (ICC). One-way ANOVA was used to compare the mean values of the three different positions and pairwise comparisons were performed using the Bonferroni test. Statistical analyses were performed using SPSS Software (Version 17.0, Statistical Package for the Social Sciences, SPSS Inc., Chicago, Ill., USA) and p values less than 0.05 were considered significant.

## Results

A total of 20 patients (7 female and 13 male) were enrolled in the study. Mean patient age was 60 years and mean BMI was 27. Our measurements reveal that aorta moves closer to the T5-T7 vertebrae in all three different positions (**Figure 3**). In particular, in supine position, the minimum distance B decreases gradually from T4 to T7 and then, continuing to lower levels of the thoracic spine, increases again. The minimum distance B connecting left pedicle entry point to the edge of the aortic wall is summarized in Table 1. Statistical analysis showed significant difference in distance B between the three different patient positions per level (**Table 1**) while it was not affected by sex and body mass index of


the patient. By creating a scatter plot of Bx and By values, we observe a tendency of the aorta to shift medially and anteriorly in relation to the thoracic spine while patient changes from supine in prone and prone with padding position (**Figure 4**). Therefore, aortic wall tends to be closer to the left pedicle screw with the patient in prone with padding position.

## Discussion

In 20 patients with scoliotic deformity, the position of the aorta compared with the thoracic spine (levels T4 to T12) was studied, with the patient in supine, prone and prone with padding surgical position. Significant displacement of the aortic wall was observed as the patient was transferred from supine to prone position. Jiang et al. have studied 26 patients with idiopathic right thoracic scoliosis using MRI in both supine and prone positions and have shown similar results [5]. Nevertheless, in this study patients were not investigated in prone with padding position. In the present study the anterior-posterior By distance significantly increased from the left spinal cord to the aortic wall when the patient was placed in prone with padding position. According to our knowledge, there is no other study in the literature to compare the standard supine with the prone with padding position. Sucato et al investigated the anatomic relationship between aorta and thoracic spine in scoliotic and non-scoliotic patients and demonstrated a more anterior position of the aorta in patients with left thoracic scoliosis compared to a more posterior position in patients with right thoracic scoliosis [6,7]. Finally, Vaccaro et al. studied 19 non-scoliotic patients and noted that the aorta is at higher risk of injury when the pedicle screw penetrates the anterior vertebral cortex [8]. This study concludes that iatrogenic vascular injury is higher when the patient is placed in the prone with padding position. In contrast to previous studies we calculated the minimum safe distance, to avoid iatrogenic aortic wall injury by a pedicle screw. Both in posterior and anterior approaches the understanding of the relative position of the aorta defines the safe placement zone of the pedicle screw. Although di-



rect iatrogenic injury is rarely reported, direct contact of hardware with the aorta has been reported up to 17% of patients undergoing thoracic spinal surgery [9]. Thus, our findings may be useful in preoperative planning of thoracic spine surgery. The position of the aorta should be checked by imaging -either CT or MRI- with the patient in both supine and prone positions. Aortic displacement estimation would allow the surgeon to decide on the appropriate surgical approach aiming at the safe positioning of pedicle screws. As shown, aorta position is dependent on patient position which

in turn is largely determined by the surgical approach selected. Prone and prone with padding surgical position significantly influence relative aortic wall position and distance from the thoracic spine. Preoperative planning should take into account these observed changes, acknowledging that imaging in supine position depicts a defined static relationship which probably differs remarkably from surgical anatomical reality. 

**Conflict of interest:**

The authors declared no conflicts of interest.

## REFERENCES

1. Bridwell KH. Indications and techniques for anterior-only and combined anterior and posterior approaches for thoracic and lumbar spine deformities. *Instr Course Lect* 2005; 54: 559-65.
2. Wong HK, Hee HT, Yu Z, Wong D. Results of thoracoscopic instrumented fusion versus conventional posterior instrumented fusion in adolescent idiopathic scoliosis undergoing selective thoracic fusion. *Spine (Phila Pa 1976)* 2004; 29: 2031-8; discussion 9.
3. Wegener B, Birkenmaier C, Fottner A, Jansson V, Durr HR. Delayed perforation of the aorta by a thoracic pedicle screw. *Eur Spine J* 2008; 17 Suppl 2:S351-4.
4. Tschoeke SK, Gahr P, Krug L, Kasper AS, Heyde CE, Ertel W. Late diagnosis of pedicle screw malplacement with perforation of the thoracic aorta after posterior stabilization in a patient with multiple myeloma: case report. *Spine (Phila Pa 1976)* 2011; 36: E886-90.
5. Jiang H, Qiu X, Wang W, et al. The position of the aorta changes with altered body position in single right thoracic adolescent idiopathic scoliosis: a magnetic resonance imaging study. *Spine (Phila Pa 1976)* 2012; 37: E1054-61.
6. Milbrandt TA, Sucato DJ. The position of the aorta relative to the spine in patients with left thoracic scoliosis: a comparison with normal patients. *Spine (Phila Pa 1976)* 2007; 32: E348-53.
7. Sucato DJ, Duchene C. The position of the aorta relative to the spine: a comparison of patients with and without idiopathic scoliosis. *J Bone Joint Surg Am* 2003; 85-A: 1461-9.
8. Vaccaro AR, Rizzolo SJ, Balderston RA, et al. Placement of pedicle screws in the thoracic spine. Part II: An anatomical and radiographic assessment. *J Bone Joint Surg Am* 1995; 77: 1200-6.
9. Huitema GC, van Rhijn LW, van Ooij A. Screw position after double-rod anterior spinal fusion in idiopathic scoliosis: an evaluation using computerized tomography. *Spine (Phila Pa 1976)* 2006; 31: 1734-9.

READY - MADE  
CITATION

Plataniotis N, Evangelopoulos DS, Bakalakos M, Vlamis J, Pneumáticos S. The effect of patient positioning on the relative positioning of the aorta to the thoracic spine in patients with scoliosis. *Acta Orthop Trauma Hell* 2018; 69(3): 132-138.

## ΠΕΡΙΛΗΨΗ

Μία σπάνια αλλά βαρύτατη επιπλοκή της χειρουργικής αντιμετώπισης προβλημάτων της θωρακικής μοίρας της Σπονδυλικής Στήλης, αποτελεί η ιατρογενής τρώση της αορτής κατά την τοποθέτηση των διαυχενικών κοχλίων. Η ανατομία της κατιούσας θωρακικής αορτής και η σχέση της με τη θωρακική μοίρα της Σπονδυλικής Στήλης, αποτελούν κρίσιμα στοιχεία του προεγχειρητικού ελέγχου. Σκοπός της παρούσας μελέτης είναι η αξιολόγηση της μετατόπισης της αορτής σε σχέση με τη Σπονδυλική Στήλη (Θ4-Θ12) σε ύπτια, πρηνή και χειρουργική πρηνή θέση, σε ασθενείς με σκολίωση. Είκοσι ασθενείς υποβλήθηκαν σε Αξονική Τομογραφία της θωρακικής μοίρας της Σπονδυλικής Στήλης και υπολογίστηκε η ελάχιστη απόσταση από το σημείο εισόδου του αριστερού διαυχενικού κοχλία μέχρι το τοίχωμα της θωρακικής αορτής. Η στατιστική ανάλυση ανέδειξε στατιστικά σημαντική διαφορά της απόστασης ανάμεσα στις τρεις διαφορετικές θέσεις για κάθε επίπεδο. Πιο συγκεκριμένα, το αορτικό τοίχωμα έχει την τάση να βρίσκεται πιο κοντά στον αριστερό διαυχενικό κοχλία με τον ασθενή σε χειρουργική πρηνή θέση. Συνεπώς, τα ευρήματα αυτά είναι χρήσιμα στην εκτίμηση της μετατόπισης της αορτής σε σχέση με τη θέση του ασθενούς και επιτρέπουν στο χειρουργό να επιλέξει την κατάλληλη προσέλαση κάθε φορά, ώστε να εξασφαλίσει την ασφαλή τοποθέτηση των διαυχενικών κοχλίων.

**ΛΕΞΕΙΣ ΚΛΕΙΔΙΑ:** Χειρουργική σπονδυλικής στήλης, τοπογραφία θωρακικής αορτής